



## Toxicological Effects of 30-Day Intake of Malathion on the Male Reproductive System of Wistar Rats

I. Flehi-Slim<sup>1</sup>, S. Boughattas<sup>1\*</sup>, Y. Belaïd-Nouira<sup>1</sup>, A. Sakly<sup>1</sup>, F. Neffati<sup>2</sup>, M.F. Najjar<sup>2</sup>, Z. Haouas<sup>1</sup>, H. Ben Cheikh<sup>1</sup>

1. Research Unity of Genetic (02/UR/08-03), Laboratory of Histology and Cytogenetic, Faculty of Medicine, Monastir, Tunisia

2. Laboratory of Biochemistry-Toxicology, University Hospital of Monastir, Tunisia

### HIGHLIGHTS

- Weight of rat testes treated from Malathion (MAL) was significantly lower than the control group.
- No significant difference was found between body weight of the control and the treatment rats.
- MAL induced histopathological changes in testes of rats and disturbance in sex hormones levels.

### Article type

Original article

### Keywords

Malathion

Testis

Rats

Toxicology

### Article history

Received: 15 Jul 2016

Revised: 29 Sep 2016

Accepted: 13 Oct 2016

### Acronyms and abbreviations

MAL=Malathion

LH=Luteinizing Hormone

FSH=Follicle-Stimulating Hormone

### ABSTRACT

**Background:** Malathion (MAL) is a choice insecticide in the stored grain in different countries. The aim of the present study is to evaluate toxicological effects of 30-day intake of MAL on the male reproductive system of Wistar rats.

**Methods:** This research was ethically approved by the local authority at Faculty of Medicine, Monastir, Tunisia. Three MAL treated groups received 1 ml corn oil containing 1.3, 13.7, and 137 mg/kg body weight/day, respectively. Body and testes weights, testosterone, Luteinizing Hormone (LH) and Follicle-Stimulating Hormone (FSH) levels were measured. Histopathological sections were prepared from testes of animals and stained with hematoxylin and eosin and also Masson trichrome. Statistical analysis was done using SPSS for windows version 10.

**Results:** A meaningful decrease ( $p<0.05$ ) in the testes weight of treatment groups was observed compared to the control animals. However, no significant difference ( $p>0.05$ ) was found between body weight of control and treatment groups. All the three MAL-treated rats had significantly ( $p<0.05$ ) lower plasma FSH, LH, and testosterone levels than the control group. Some major histopathological changes were found in testes sections of treatment groups.

**Conclusion:** Our study revealed that subchronic and relatively short time exposure of male Wistar rats to MAL can induce histopathological changes in testes and disturbance in sex hormones levels in a dose-dependent manner.

### Introduction

Pesticides as a heterogeneous group of chemical products are widely used in producing crops to control pests such as insects, rodents, weeds, mold, etc. Organophosphate pesticides, the most used insecticides, are widely used in agriculture having high exposure possibility for human or livestock especially through consumption

of contaminated foodstuffs (Raghu et al., 2014; Rezg et al., 2010). Although, the primary toxicity associated with acute exposure to these pesticides is cholinergic symptom resulting from acetylcholinesterase inhibition, pesticides have usually numerous compound-specific chronic effects especially developmental abnormality, immunotoxicity, carcinogenesis, and also reproductive

\* Corresponding author. ✉ sbgh@mail.com

**To cite:** Flehi-Slim I, Boughattas S, Belaïd-Nouira Y, Sakly A, Neffati F, Najjar M.F., Haouas Z, Ben Cheikh H. (2016). Toxicological effects of 30-day intake of malathion on the male reproductive system of Wistar rats. *Journal of Food Quality and Hazards Control*. 3: 152-156.

toxicity (Menezes de Carvalho et al., 2014; Dhoub et al., 2015; Sultatos, 1994; Tamura et al., 2001). Considerable increasing rate of testicular abnormalities over a short time is probably related to environment rather than the genetic risk factors (Giwerzman et al., 1993; Oehninger, 2001). It is known that many chemical agents can affect the reproductive performance of mammalian (Sanchez-Pena et al., 2004).

Among organophosphate pesticides, Malathion (MAL) with chemical compound of S-1,2(bis ethoxycarbonyl) ethyl O,O dimethyl phosphorodithioate is the most commonly used. MAL is a choice in the stored grain in different countries because of its high potency to a wide range of pests and its relatively low toxicity in mammalian (Flehi-Slim et al., 2015; Rezg et al., 2010; Wang et al., 2014). So, the aim of the present study is to evaluate toxicological effects of 30-day intake of MAL on the male reproductive system of Wistar rats.

## Materials and methods

### Ethics

This research was ethically approved by the local authority at Faculty of Medicine, Monastir, Tunisia.

### Chemicals

MAL (Fyfanon® 50 EC 500 g/L) of commercial grade was used in this study. All the other chemicals were of analytical grade and obtained from local commercial sources.

### Animals

Male Wistar rats weighted 150-180 g and aged 6–8 weeks obtained from SIPHAT Company (Pharmaceutical Industrial Society of Tunisia, Ben Arous, Tunisia). Animals were acclimatized during one week before the experiments. They were randomly assigned to one control group (n=6) and three different treatment groups (n=6) and housed at  $21 \pm 5$  °C with a 12 h light/dark cycle as well as 55% humidity. The rats were fed a standard commercial pellet diet from Sico Company (Sfax, Tunisia) and drinking water *ad libitum*.

### Treatment

Animals were treated for 30 days by gavages using stomach tube. The three MAL treated groups received 1 ml corn oil containing 1.3 (dose 1), 13.7 (dose 2), and 137 (dose 3) mg/kg body weight/day, respectively. Control groups received equal amount of corn oil. Body weight was recorded weekly through the experiment.

### Blood sampling and sex hormone analysis

At the end of treatment period, each animal was anesthetized by ether and 5 ml of blood was sampled by heart

tapping. Heparinized tubes containing blood were then centrifuged at 3000 rpm during 5 min and obtained plasma was conserved at -80 °C. Plasma testosterone, Luteinizing Hormone (LH) and Follicle-Stimulating Hormone (FSH) level were measured by electrochemiluminescence assay with automate Cobas 6000 (Roche Diagnostics, Switzerland).

### Histopathology

Body and testes weights of each group were measured. The testes were dissected and tissue samples were fixed in Bouin's solution, processed in a series of graded ethanol, and embedded in paraffin. Paraffin sections were cut at 5 µm thickness and stained with hematoxylin and eosin and also Masson trichrome for light microscopy.

### Statistical analysis

The data for various biochemical parameters were expressed as mean±Standard Deviation (SD) and compared using T-test. Values were considered statistically significant when  $p < 0.05$ . Statistical analysis was done using SPSS for windows version 10.

## Results

Changes detected in body and testes's weight in experimental and control groups are summarized in Table 1. A meaningful decrease ( $p < 0.05$ ) in the testes weight of treatment groups was observed compared to the control animals. To make a functional comparison of weight gain or loss, tissue weight per 100 g body weight was calculated. The testes showed significant ( $p < 0.05$ ) weight reduction per 100 g body weight among the three treated groups. However, no significant difference ( $p > 0.05$ ) was found between body weight of control and treatment groups. Table 2 shows that all the three MAL-treated rats had significantly ( $p < 0.05$ ) lower plasma FSH, LH, and testosterone levels than the control group.

Fig. 1A and Fig. 2A represent photomicrographs of testes from the control group with normal testicular histology stained with hematoxylin and eosin and also Masson trichrome, respectively. The normal structures of spermatogenic cells and sertoli cells in the seminiferous tubules have been conserved. Leydig cells and blood vessels were found in the interstitial connective tissue between the tubules. The seminiferous tubules appeared uniform in size and shape. They were lined by regularly arranged rows of spermatogenic cells in different stages of maturation. Meanwhile sections from MAL treated rats (1.3 mg/kg body weight/day) showed a decrease in the number of spermatide and spermatozoa in seminiferous tubules lumen and a general reduction in the size of seminiferous tubules (Fig. 1B and Fig. 2B). Sections

from MAL treated animals with 13.7 mg/kg body weight/day revealed stopped spermatogenesis and discontinuity or dyscohesive basal germ cells. In addition, basal germ cells, and primary and secondary spermatocytes showed typical features of apoptosis. An abnormal aspect of spermatozoa flagella into a large number of seminiferous tubules was also observed (Fig. 1C and Fig. 2C). After the third administrated of MAL dose of 137 mg/kg body weight/day, we observed that most tubules contained apoptotic bodies. There are also absence of

spermatozoa in the lumen of seminiferous tubules, thickness of basement of spermatozoa in the lumen of seminiferous tubules, and thickness of basement membrane accompanied by an important regression of interstitial tissue and Leydig cells. We recorded some abnormal tubules conformity in comparison with sections obtained from testes of control group. The highest MAL dose induced an important deformation as well as a dyscohesive aspect of whole tubules (Fig. 1D and Fig. 2D).

**Table 1:** Body and testes weights of rats after administration of different doses of MAL for 30 days

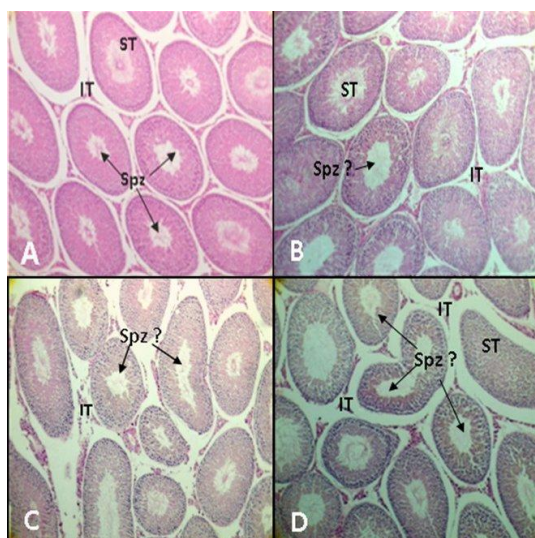
Groups	Initial body weight (g)	Final body weight (g)	Absolute testes weight (g)	Relative testes weight (g/100 g body weight)
Control	166.65±9.62	187.06±8.89	2.34±3.76	1.25±6.21
Dose 1	164.96±7.65	186.08±6.88	2.12±3.40	1.14±2.60
Dose 2	168.41±8.11	179.43±9.48	1.87±5.25	1.04±7.76
Dose 3	166.1±9.42	184.69±7.91	1.68±3.22	0.91±3.12

Values are expressed as means±SD; n=6 for each treatment group

**Table 2:** Plasma levels of FSH, LH, and testosterone of rats after administration of different doses of MAL for 30 days

Groups	Testosterone (ng/L)	FSH (U/L)	LH (U/L)
Control	3.91±0.19	2.87±7.09	8.52±6.26
Dose 1	3.63±0.12	2.39±7.79	8.18±4.09
Dose 2	2.97±4.98	1.33±6.75	5.87±4.09
Dose 3	2.41±7.95	1.01±6.26	5.34±2.8

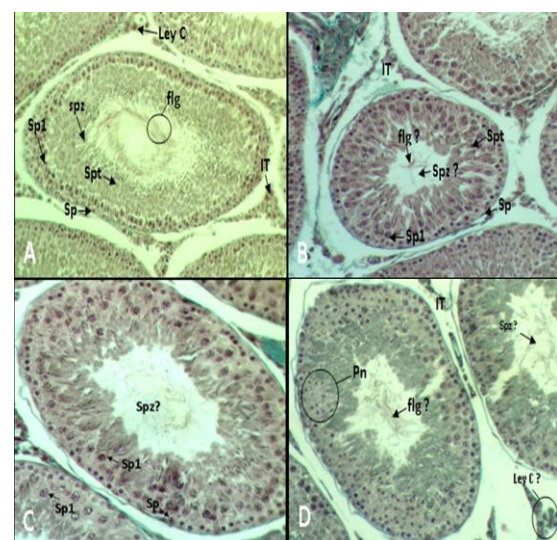
Values are expressed as means±SD; n=6 for each treatment group



**Fig. 1:** Histological sections testes stained with hematoxylin and eosin ( $\times 100$ ). A: control group. B: treated group with 1.37 mg/kg body weight/day of MAL. C: treated group with 13.7 mg/kg body weight/day of MAL. D: treated group with 137 mg/kg body weight/day of MAL. Spz: spermatozoa; IT: interstitial tissue; Spz?: abnormal spermatozoa; ST: seminiferous tubules

## Discussion

In the current research, even though MAL was given at relatively low levels of 1/1000, 1/100, and 1/10 of the oral LD<sub>50</sub>, it was found some pathological changes in



**Fig. 2:** Histological sections testes stained with Masson trichrome ( $\times 320$ ). A: control group. B: treated group with 1.37 mg/kg body weight/day of MAL. C: treated group with 13.7 mg/kg body weight/day of MAL. D: treated group with 137 mg/kg body weight/day of MAL. Spz: spermatozoa; flg: flagella; IT: interstitial tissue; Spt: spermatide; Sp: spermatogonia; Sp1: spermatocyte I; Ley C: Leydig cells; Spz?: abnormal spermatozoa; Pn: pycnotic nuclei; flg?: abnormal flagella; Ley C?: decrease of Leydig cells

animals, although no rat died during the period of the study. It was found a significant decrease in absolute and relative testes weight in a dose-dependent manner. In

fact, we noted a gonadic atrophy among the treated rats compared to controls. These results are in agreement with those found by Anderson et al. (2002), which mentioned that testicular weight of Wistar rats treated by deltamethrin (pyrethroids) was reduced at the dose of 4.0 mg/kg body weight. The significant decline in testicular weight may be due to decrease in the number of spermatogenic elements and spermatozoa. It was previously showed that some pesticides may result in some histopathological changes in male reproduction system of mammalian (Mahgoub and El-Medany, 2001; Uzunhisarcikli et al., 2007) and also the reduction of spermatogenesis (Geng et al., 2015; Khan et al., 2001) that are similar to our findings. In addition, Xu et al. (2004) showed reduction of daily sperm production in male rats exposed to organophosphate pesticides named phoxim, along with fenvalerate, a pyrethroid insecticide. Organophosphate pesticides do not decrease only sperm counts but also reduce sperm motility (Khan et al., 2001; Uzunhisarcikli et al., 2007). Also, it was shown by some researchers that animals exposed to pesticides; produce more dead or abnormal spermatozoa (Contreras and Bustos-Obregon, 1999; Uzunhisarcikli et al., 2007). According to the mentioned previous reports, the pathological changes are concentration-dependent with higher intensify when the animals are exposed longer, that are in according to the results of the present study. Epidemiological research about the acute and chronic toxicity of MAL indicates that this chemical product is toxic to various organs of the mammals (Rezg et al., 2010). Mammals are expected to be adversely affected by oral, dermal, and inhalation exposure to MAL (Brand et al., 2005; Edwards et al., 2007; Lasram et al., 2008; Rezg et al., 2008a; Wang et al., 2014). Toxic effects of MAL can also be observed on fish, chicks, and non-target invertebrates (Senger et al., 2005; Sodhi et al., 2008). The oral LD<sub>50</sub> of MAL for male rats is 1350 mg/kg (John et al., 2001). However, Rezg et al. (2008b) reported hepatic damage as well as biochemical changes in rats received 100 mg/kg of MAL, intragastrically.

Organophosphate pesticides may also affect male reproductive function by decreasing FSH, LH, and testosterone levels. Similar to our findings, significant alterations in FSH, LH, and testosterone levels have been reported after exposure to other pesticides such as abamectin (Elbetieha and Da'as, 2003) and methyl parathion (Maitra and Mitra, 2008). However, Mahgoub and El-Medany (2001) found that pesticides increase FSH and LH levels. LH and FSH activity depends both on the quantity of these hormones and the frequency of specific receptors in the testis. It has been reported that exposure to some environmental hazards affects testicular function through reduction of pituitary LH secretion as well as Leydig cell steroidogenesis (Akingbemi et al., 2004;

Murugesan et al., 2007). In the current study, FSH and LH levels in all the three doses-treated rats have been significantly decreased compared to control rats. This could be the result of the fact that some insecticides like chlorpyrifos, as an organophosphate, were reported to affect hypothalamic Gonadotrophic Releasing Hormone (GnRH) gene expression and reduce LH and FSH (Gore, 2001; Pudungtod et al., 1998; Smallridge et al., 1991). On the other hand, some investigations indicated that the major location of androgenic hormone biosynthesis is in testicular Leydig cells. So, this observation is consistent with earlier reports which had shown that factors could inhibit steroidogenesis by reducing cAMP formation in Leydig cells (Stocco and Clark, 1996). It is worth noting that Valenti et al. (1997) and Ronco et al. (2001) concluded that fenvalerate pesticide may disturb the cAMP formation to make the negative action on steroidogenesis.

## Conclusion

In conclusion, our study revealed that subchronic and relatively short time exposure of male Wistar rats to MAL can induce histopathological changes in testes and disturbance in sex hormones levels in a dose-dependent manner.

## Conflicts of interest

The authors have not any conflicts of interest to declare.

## Acknowledgments

Authors would like to thank Dr. Emna Kerkeni for her scientific help and critical comments. The financial support of this study was provided by Ministry of Higher Education, Scientific Research and Technology, Tunisia (Code No.02/UR/08-03).

## References

- Akingbemi B.T., Sottas C.M., Koulova A.I., Klinefelter G.R., Hardy M.P. (2004). Inhibition of testicular steroidogenesis by xenoestrogens bisphenol A is associated with reduced pituitary luteinizing hormone secretion and decreased steroidogenic enzymes gene expression in rat Leydig cells. *Endocrinology*. 145: 592-603.
- Anderson J.M.A., Araujo S., Santana G.M., Ohi M., Dalsenter P.R. (2002). Reproductive effects of deltamethrin on male offspring of rats exposed during pregnancy and lactation. *Regulatory Toxicology and Pharmacology*. 36: 310-317.
- Brand R.M., Charron A.R., Brand R.E. (2005). Decreasing malathion application time for lice treatment reduces transdermal absorption. *International Journal of Pharmaceutics*. 301: 48-53.
- Contreras H.R., Bustos-Obregon E. (1999). Morphological alterations in mouse testis by a single dose of malathion. *Journal of Experimental Zoology*. 284: 355-359.



- Dhouib I.E.B., Lasram M.M., Annabi A., Gharbi N., El-Fazaa S. (2015). A comparative study on toxicity induced by carbosulfan and malathion in Wistar rat liver and spleen. *Pesticide Biochemistry and Physiology*. 124: 21-28.
- Edwards J.W., Lee S., Heath L.M., Pisaniello D.L. (2007). Worker exposure and a risk assessment of malathion and fenthion used in the control of Mediterranean fruit fly in South Australia. *Environmental Research*. 103: 38-45.
- Elbetieha A., Da's S.I. (2003). Assessment of antifertility activities of abamectin pesticide in male rats. *Ecotoxicology and Environmental Safety*. 55: 307-313.
- Flehi-Slim I., Chargui I., Boughattas S., El Mabrouk A., Belaid-Nouira Y., Neffat F., Najjar M.F., Haouas Z., Cheikh H.B. (2015). Malathion-induced hepatotoxicity in male Wistar rats: biochemical and histopathological studies. *Environmental Science and Pollution Research*. 22: 17828-17838.
- Geng X., Shao H., Zhang Z., Ng J.C., Peng C. (2015). Malathion-induced testicular toxicity is associated with spermatogenic apoptosis and alterations in testicular enzymes and hormone levels in male Wistar rats. *Environmental Toxicology and Pharmacology*. 39: 659-667.
- Giweraman A., Carlsen E., Keiding N., Skakkebk N.E. (1993). Evidence for increasing incidence of abnormalities of the human testis: a review. *Environmental Health Perspectives*. 101: 65-71.
- Gore A.C. (2001). Environmental toxicant effects on neuroendocrine function. *Endocrine*. 14: 235-246.
- John S., Kale M., Rathore N., Bhatnagar D. (2001). Protective effect of vitamin E in dimethoate and malathion induced oxidative stress in rat erythrocytes. *The Journal of Nutritional Biochemistry*. 12: 500-504.
- Khan I.A., Reddy B.V., Mahboob M., Rahman M.F., Jamil K. (2001). Effects of phosphorothionate on the reproductive system of male rats. *Journal of Environmental Science and Health, Part B*. 36: 445-456.
- Lasram M.M., Annabi A.B., Rezg R., Elj N., Slimen S., Kamoun A., El-Fazaa S., Gharbi N. (2008). Effect of short-time malathion administration on glucose homeostasis in Wistar rat. *Pesticide Biochemistry and Physiology*. 92: 114-119.
- Mahgoub A.A., El-Medany A.H. (2001). Evaluation of chronic exposure of the male rat reproductive system to the insecticide methomyl. *Pharmaceutical Research*. 44: 73-80.
- Maitra S.K., Mitra A. (2008). Testicular functions and serum titers of LH and testosterone in methyl parathion-fed resorcing parakeets. *Ecotoxicology and Environmental Safety*. 71: 236-244.
- Menezes de Carvalho M.T., Celotto A.C., Sumarelli Albuquerque A.A., Garros Ferreira L., Capellini V.K., Cassiano Silveira A.P., Rubens de Nadai T., Evora P.R.B. (2014). *In vitro* effects of the organophosphorus pesticide malathion on the reactivity of rat aorta. *Pharmacology*. 94: 157-162.
- Murugesan P., Muthusamy T., Balasubramanian K., Arunakaran J. (2007). Effects of vitamins C and E on steroidogenic enzymes mRNA expression in polychlorinated biphenyl (Aroclor 1254) exposed adult rat Leydig cells. *Toxicology*. 232: 170-182.
- Oehninger S. (2001). Strategies for the infertile man. *Seminars in Reproductive Medicine*. 19: 231-237.
- Pudungtod C., Lasley B.L., Christiani D.C., Rayan L.M., Xu X. (1998). Reproductive hormone profile among pesticide factory workers. *Journal of Occupational and Environmental Medicine*. 40: 1038-1047.
- Raghu P., Reddy T.M., Reddaiah K., Swamy B.K., Sreedhar M. (2014). Acetylcholinesterase based biosensor for monitoring of malathion and Acephate in food samples: a voltammetric study. *Food Chemistry*. 142: 188-196.
- Rezg R., Mornagui B., Benahmed M., Chouchane S.G., Belhajmida N., Abdeladhim M., Kamoun A., El-fazaa S., Gharbi N. (2010). Malathion exposure modulates hypothalamic gene expression and induces dyslipidemia in Wistar rats. *Food and Chemical Toxicology*. 48: 1473-1477.
- Rezg R., Mornagui B., El-Fazaa S., Gharbi N. (2008a). Caffeic acid attenuates malathion induced metabolic disruption in rat liver, involvement of acetylcholinesterase activity. *Toxicology*. 250: 27-31.
- Rezg R., Mornagui B., El-Fazaa S., Gharbi N. (2008b). Biochemical evaluation of hepatic damage in subchronic exposure to malathion in rats: effect on superoxide dismutase and catalase activities using native PAGE. *Comptes Rendus Biologies*. 331: 655-662.
- Ronco A.M., Valedes K., Marcus D., Llanos M. (2001). The mechanism for lindane-induced inhibition of steroidogenesis in cultured rate Leydig cells. *Toxicology*. 159: 99-106.
- Sanchez-Pena L.C., Reyes B.E., Lopez-Carrillo L., Recio R., Moran-Martinez J., Cebrian M.E., Quintanilla-Vega B. (2004). Organophosphorous pesticide exposure alters sperm chromatin structure in Mexican agricultural workers. *Toxicology and Applied Pharmacology*. 196: 108-113.
- Senger M.R., Rico E.P., Arizi M.B., Rosemberg D.B., Dias R.D., Bogo M.R., Bonan C.D. (2005). Carbofuran and malathion inhibit nucleotide hydrolysis in zebrafish (*Danio rerio*) brain membranes. *Toxicology*. 212: 107-115.
- Smallridge R.C., Carr F.E., Fein H.G. (1991). Diisopropylfluorophosphate (DFP) reduces serum prolactin, thyrotropin, luteinizing hormone, and growth hormone and increases adrenocorticotropine and corticosterone in rats: involvement of dopaminergic and somatostatinergic as well as cholinergic pathways. *Toxicology and Applied Pharmacology*. 108: 284-295.
- Sodhi S., Sharma A., Brar A.P.S., Brar R.S. (2008). Effect of a tocopherol and selenium on antioxidant status, lipid-peroxidation and hepatopathy induced by malathion in chicks. *Pesticide Biochemistry and Physiology*. 90: 82-86.
- Stocco D.M., Clark B.J. (1996). Regulation of the acute production of steroids in steroidogenic cells. *Endocrine Reviews*. 17: 221-244.
- Sultatos L.G. (1994). Mammalian toxicology of organophosphorous pesticides. *Journal of Toxicology and Environmental Health*. 43: 271-289.
- Tamura H., Maness S.C., Reischmann K., Dorman D.C., Gray L.E., Gaido K.W. (2001). Androgen receptor antagonism by the organophosphate insecticide fenitrothion. *Toxicological Sciences*. 60: 56-62.
- Uzunhisarcikli M., Kalender Y., Dirican K., Kalender S., Ogutcu A., Buyukkomurcu F. (2007). Acute, subacute and subchronic administration of methyl parathion induced testicular damage in male rats and protective role of vitamins C and E. *Pesticide Biochemistry and Physiology*. 87: 115-122.
- Valenti S., Guido R., Fazzuoli L., Barreca A., Giusti M., Giordano G. (1997). Decreased steroidogenesis and cAMP production *in vitro* by Leydig cells isolated from rats make hypothyroid during adulthood. *International Journal of Andrology*. 20: 279-286.
- Wang P., Wang H.P., Xu M.Y., Liang Y.J., Sun Y.J., Yang L., Li L., Li W., Wu Y.J. (2014). Combined subchronic toxicity of dichlorvos with malathion or pirimicarb in mice liver and serum: a metabonomic study. *Food and Chemical Toxicology*. 70: 222-230.
- Xu L.C., Zhan N.Y., Liu R., Song L., Wang X.R. (2004). Joint action of phoxim and fenvalerate on reproduction in male rats. *Asian Journal of Andrology*. 6: 337-341.