



Application of Morphological Method for Detection of Unauthorized Tissues in Processed Meat Products

R. Latorre¹, J. Sadeghinezhad², B. Hajimohammadi³, F. Izadi^{3*}, M.T. Sheibani²

1. Department of Medical and Surgical Science, University of Bologna, Bologna, Italy

2. Department of Basic Sciences, Faculty of Veterinary Medicine, University of Tehran, Tehran, Iran

3. Research Center for Molecular Identification of Food Hazards, Shahid Sadoughi University of Medical Sciences, Yazd, Iran

Article type

Short communication

Abstract

Keywords

Meat Products
Histology
Analysis

Received: 28 Nov 2014

Revised: 19 Dec 2014

Accepted: 21 Jan 2015

Background: Nowadays, there is an increase of meat and animal carcass consumption worldwide. Due to the economic value of meat, the likelihood of using unauthorized tissue is possible in meat products. Based on these observations, the aim of the present study was to apply morphological method for detection of unauthorized tissues in processed meat products.

Methods: In this study, a total of 20 samples of different types of processed meat products including Kabab Loghme (n=5), sausage (n=5), handmade hamburger (n=5) and Kabab Koobideh (n=5) were randomly collected from restaurants and supermarkets in Iran. The samples were divided into three parts and then, one piece was taken from each part for the histological study. The tissues were fixed in 10% neutral-buffered formalin and were dehydrated and embedded in paraffin and routinely processed for light microscopy. The paraffin-embedded blocks were cut into 6 µm sections and stained using hematoxylin and eosin (H&E) for histological study.

Results: The skeletal muscle tissues were visible clearly in all samples. A wide range of unauthorized tissues have been detected including connective tissue (n=20), gizzard (n=2), adipose tissue (n=7), soya (n=11), cartilage (n=5) and ovary (n=1).

Conclusion: The present study showed the use of unauthorized tissues in Iranian processed meat products which were detectable by histological method. Therefore, histological technique may be a simple and economic tool for evaluation of the meat adulteration and to improve hygiene and meat quality.

Introduction

Meat products are known to constitute at least half of commercialized meat and technologically include heated, cooked, raw and processed meat products. Based on Iranian national standard view point, the use of undesirable organs of slaughter animals, including the visceral organs, hyaline cartilage, skin, fat and bone instead of meat in heated meat products is considered as fraud (Rokni, 2008). Aside from the adulteration aspect, some animal

tissues such as central nervous tissues can be a vector of infective agents which are transmissible to human beings (Herde et al., 2005). Furthermore, some vegetable additives in meat products have been known as allergens (Pospiech et al., 2009).

Due to the high economic value of meat, the use of unauthorized tissue in meat products is undesirable but possible. Previously, some researchers have reported histological methods as an effective technique to detect unauthorized tissues in some meat products (Disbrey and

*Corresponding author

E-mail: izadifarkhonde@yahoo.com

Ruck, 2000; Prayson et al., 2008a; Prayson et al., 2008b; Rezaian and Rokni, 2001; Rokni et al., 1999). Based on these observations, the aim of the present study was to apply morphological method for detection of unauthorized tissues in processed meat products.

Materials and methods

In this study, a total of 20 samples of different types of processed meat products including Kabab Loghme (n=5), sausage (n=5), handmade hamburger (n=5) and Kabab Koobideh (n=5) were randomly collected from restaurants and supermarkets in Iran.

The characteristics of the samples, including sample type and date of sampling, were recorded and then all the samples were immediately were transported to the histology laboratory.

Each sample was divided into three equal parts and then, four pieces were taken from each part. The tissues were fixed in 10% neutral-buffered formalin and were embedded in paraffin and routinely processed for light microscopy. The paraffin-embedded blocks were cut into 6 μ m sections and stained using hematoxylin and eosin

(H&E) for histological study. The slides were observed under a microscope (N-180 M, NOVEL, Beijing, China) equipped with electronic eyepiece (MD130, OME-TOP system, New Taipei City, Taiwan) to detect unauthorized tissues and were processed using Photoshop software CS (Adobe system, San Joze, CA, USA).

Results

Light microscopy showed relatively preserved skeletal muscle in samples of Kabab Loghme, handmade hamburger and Kabab Koobideh (Fig. 1-a). Also, light microscopy of sausage samples showed recognizable skeletal muscle with evidence of degenerative changes (Fig. 1-b).

The tissue types identified in each sample are summarized in Table 1. The most observed unauthorized tissue was connective tissue detected in all samples. Among 20 studied samples, the observed unauthorized tissues were included gizzard (n=2; Fig. 2-a), lymph node (n=1; Fig. 2-b), adipose tissue (n=7; Fig. 2-c), soya (n=11; Fig. 2-d), hyaline cartilage (n=20; Fig. 2-e), ovary (n=1; Fig. 2-f). Also, glandular tissue (n=1) was detected in the samples.

Table 1: Unauthorized tissues detected in Iranian meat products based on histological examination

Sample type	Soya	Adipose tissue	Ovary	Hyaline cartilage	Gizzard	Lymph node	Glandular tissue
Kabab Loghme (n=5)	3	2	0	0	0	0	1
Sausage (n=5)	4	0	0	5	0	1	0
Handmade hamburger (n=5)	3	3	0	0	1	0	0
Kabab Koobideh (n=5)	1	2	1	0	1	0	0

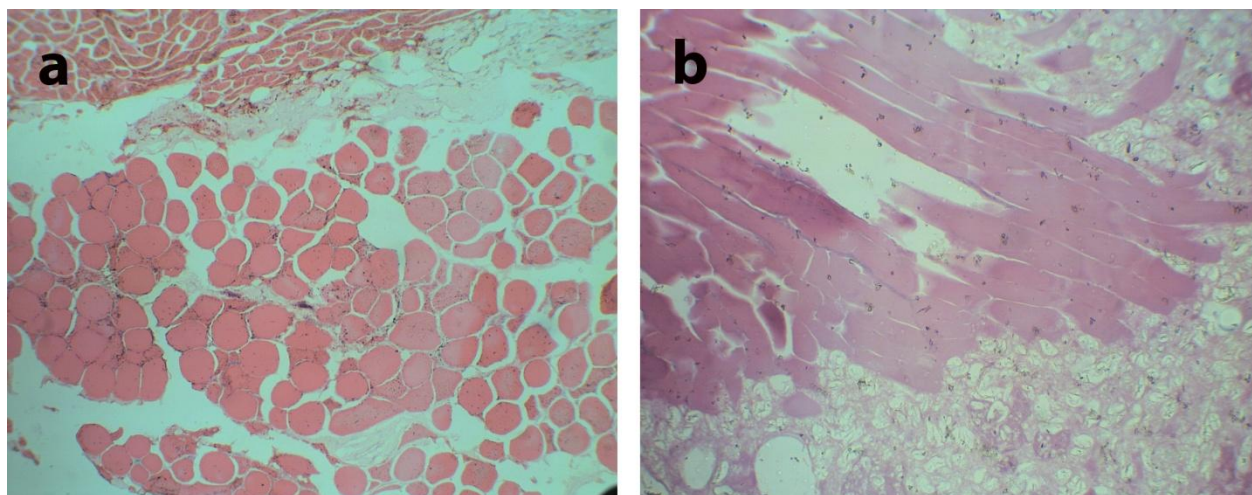


Fig. 1: Photomicrograph of skeletal muscle in Kabab Koobideh (a) sausage (b). Note the degenerative changes in skeletal muscles in sausage due to heat processing in comparison with that of Kabab Koobideh (H&E $\times 100$)

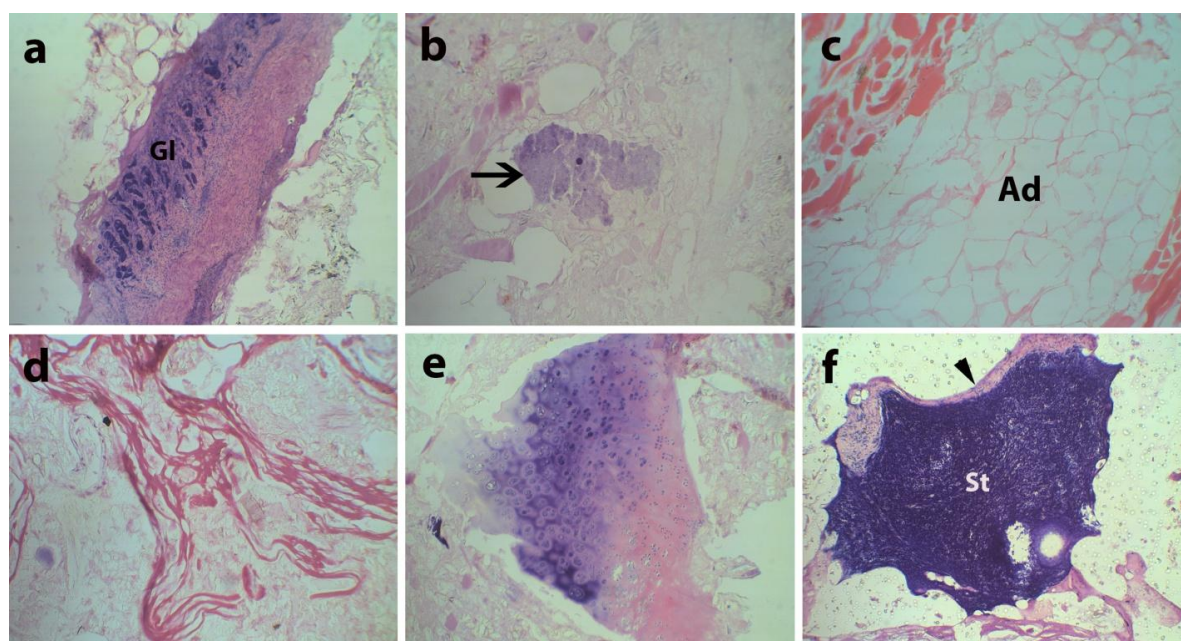


Fig. 2: Photomicrograph of unauthorized tissues in some meat products. a: histological section shows gizzard tissue in handmade hamburger. Note the visible glandular tissue (Gl) in gizzard. b: photomicrograph shows lymph node (arrow) in Kabab Loghme. c: adipose tissue (Ad) in handmade hamburger. d: cross section of soya in Kabab Loghme. e: histological section shows hyaline cartilage in sausage. f: photomicrograph shows ovary in sausage. Tunica albuginea (arrowhead) and stroma (St) are indicated (H&E $\times 100$)

Discussion

This study showed a high frequency of unauthorized tissues in various commercial meat products sold in Iran. The histological evaluation of meat products markedly showed that the formulation used in the preparation of these products do not respect the standard and hygiene food regulation and the products are not very high quality overall. The unpermitted tissues identified in this study, using microscopic examination, beside the skeletal muscle included connective tissue, gizzard, adipose tissue, soya, cartilage, ovary, lymph node and gland tissue. White hexagonal-shaped adipose tissue was detected due to the use of xylene in the histological section which dissolved the fat substances. Adipose tissue embedded in paraffin showed only the cellular membrane.

Different studies were performed for the detection of unauthorized tissues in meat products. According to histological examinations carried out in USA on eight different brands of hamburgers (Prayson et al., 2008b) and hotdogs (Prayson et al., 2008a) showed the presence of connective tissue, blood vessels, peripheral nerve, adipose tissue, plant material, cartilage and bone. Smooth muscle and soya tissues were previously detected histologically in meat products by Rokni et al. (1999). Salivary gland tissue and nuchal ligament have been detected in Iranian heated sausage which reflects the use of meat

obtained from head of slaughtered animals in meat products (Rokni et al., 1997).

In another study, 30 samples from three different types of sausages were assessed from a histological point of view. The most observed additive tissues comprised of chicken skin, hyaline cartilage, peritoneal fat and kidney (Sepehri Erayi, 2008). Sadeghi et al. (2011), in a comprehensive study, identified different percentages of unauthorized tissues including heart muscle, cartilage, bone, spleen, esophagus, and lymph nodes in 720 samples of sausage presented in Kermanshah, western Iran. A similar histological evaluation of hamburger, Kabab Loghme and minced meat which are marketed in Tehran, Iran showed the presence of some unauthorized tissues such as blood vessels, nerves, cartilage, adipose and plant material (Sepehri Erayi, 2008) that is in accordance with our findings. Almost all the mentioned studies revealed that histological examination of commercialized meat products was helpful to detect some adulterations in meat products.

Conclusion

The results of this study confirmed the use of unauthorized tissue in Iranian meat products. In conclusion, based on this evidence, control of the formulation process,

along with detailed monitoring and continuous inspection of meat products manufactures is essential to achieve quality and safety of these products.

Conflicts of interest

There is no conflict of interest.

Acknowledgement

This work was as a part of a research project funded by Shahid Sadoughi University of Medical Sciences, Yazd, Iran.

References

- Disbrey D.B., Ruck J.H. (2000). Histological laboratory methods. Edinburgh: Livingstone, London. pp: 15-46.
- Herde K., Bergmann M., Lang C., Leiser R., Wenisch S. (2005). Glial fibrillary acidic protein and myelin basic protein as markers for the immunochemical detection of bovine central nervous tissue in heat-treated meat products. *Journal of Food Protection*. 68: 823-827.
- Pospiech M., Tremlova B., Rencova E., Randulova Z. (2009). Immunohistochemical detection of soya protein- optimization and verification of the method. *Czech Journal of Food Sciences*. 27: 11-19.
- Prayson B.E., McMahon J.T., Prayson R.A. (2008a). Applying morphologic techniques to evaluate hotdogs; what is in the hotdogs we eat? *Annals of Diagnostic Pathology*. 12: 98-102.
- Prayson B., McMahon J.T., Prayson R.A. (2008b). Fast food hamburgers: what are we really eating? *Annals of Diagnostic Pathology*. 12: 406-409.
- Rezaian M., Rokni N. (2001). Histological study of heated meat products of Mazandaran province. *Pajouhesh and Sazandegi*. 15: 61-63.
- Rokni N. (2008). Meat sciences and industries. 5th edition. University of Tehran Press, Tehran. pp: 230-249.
- Rokni N., Jahed Khaniki G.R., Pousty I. (1999). Detection of unauthorized tissue in heated sausages by using histological. *Pajouhesh and Sazandegi*. 13: 76-82.
- Rokni N., Rezaian M., Dayani Dardashti A. (1997). Histological histometrical study of different heated sausages. *Journal of Veterinary Medicine, Tehran University*. 52: 95-103.
- Sepehri Eraei S. (2008). Histological methods evaluation for detection of adulteration of raw meat products supplied in Tehran. DVM thesis. Faculty of Veterinary Medicine, University of Tehran, Tehran, Iran.